



© Nurel Ertürk,
© Ahmet Oğuzhan Küçük,
© Merve Özdoğan Alın,
© Mehtap Pehlivanlar Küçük

Effectiveness of Early Combined Rehabilitation in COVID-19 Related ARDS Patients After the Successfull Application of Extracorporeal Membrane Oxygenation: Two Case Reports

COVID-19 ile İlişkili ARDS Hastalarında Ekstrakorporeal Membran Oksijenasyonun Başarıyla Uygulaması Sonrası Erken Kombine Rehabilitasyonun Etkinliği: İki Olgu Raporu

Received/Geliş Tarihi : 06.04.2022
Accepted/Kabul Tarihi : 23.05.2022

©Copyright 2022 by Turkish Society of Intensive Care
Turkish Journal of Intensive Care published by Galenos Publishing House.

Nurel Ertürk
University of Health Sciences Turkey, Ahi Evren
Thoracic and Cardiovascular Surgery Training and
Research Hospital, Cardiopulmonary Rehabilitation
Unit, Trabzon, Turkey

Ahmet Oğuzhan Küçük, Mehtap Pehlivanlar Küçük
Karadeniz Technical University Faculty of Medicine,
Department of Chest Diseases, Division of Intensive
Care Medicine, Trabzon, Turkey

Merve Özdoğan Alın
Karadeniz Technical University Faculty of Medicine,
Department of Chest Diseases, Trabzon, Turkey

Nurel Ertürk MD (✉),
University of Health Sciences Turkey, Ahi Evren
Thoracic and Cardiovascular Surgery Training and
Research Hospital, Cardiopulmonary Rehabilitation
Unit, Trabzon, Turkey

E-mail : nrlblr@gmail.com

Phone : +90 505 663 75 44

ORCID ID : orcid.org/0000-0002-9910-6336

ABSTRACT Many cardiac, pulmonary, and psychiatric complications occur due to long-term bed rest, infection, and critical illness neuropathy/myopathy in extra-corporeal membrane oxygenation (ECMO) applied coronavirus disease-2019 (COVID-19) inpatients in intensive care units. Physiotherapy plays an important role in restoring physical functions in the subacute phase following ECMO decannulation. After being discharged, and with combined rehabilitation, these patients experience a faster recovery and their quality of life increases. In this article, the effects of the combined physiotherapy program, which was applied to two patients with COVID-19 who received ECMO treatment and were discharged from the intensive care unit, is discussed. Early application of the combined rehabilitation program after discharge resulted in a positive outcome.

Keywords: COVID-19, early rehabilitation, extra-corporeal membrane oxygenation

ÖZ Yoğun bakım ünitelerinde yatan ve ekstra-korporeal membran oksijenasyonu (ECMO) uygulanan koronavirüs hastalığı-2019 (COVID-19) hastalarında uzun süreli yatak istirahati, enfeksiyon ve kritik hastalık nöropatisi/miyopatisi nedeniyle birçok kardiyak, pulmoner ve psikiyatrik komplikasyon ortaya çıkmaktadır. Fizyoterapi, ECMO dekanülasyonunu takiben subakut fazda fiziksel fonksiyonların eski haline getirilmesinde önemli bir rol oynamaktadır. Taburcu olduktan sonra, bu hastalar kombine rehabilitasyon ile daha hızlı iyileşmekte ve yaşam kaliteleri artmaktadır. Bu yazıda, ECMO tedavisi gören ve yoğun bakım ünitesinden taburcu olan COVID-19'lu iki hastaya uygulanan kombine fizyoterapi programının etkileri tartışılmaktadır. Kombine rehabilitasyon programının taburcu olduktan sonra erken uygulanması olumlu sonuçlanmıştır.

Anahtar Kelimeler: COVID-19, erken rehabilitasyon, ekstrakorporeal membran oksijenasyonu

Introduction

ECMO is an invasive supportive therapy used to treat cardiac, respiratory, or combined cardiorespiratory failure when conventional treatment options fail. Veno-venous extra-corporeal membrane oxygenation (VV-ECMO) was used effectively to treat severe respiratory failure during the influenza A (H1N1) epidemic in 2009 (1,2). The Extracorporeal Life Support Organisation recommends the use of VV-ECMO in the treatment of selected coronavirus disease-2019 (COVID-19) cases resistant to standard medical and mechanical ventilation strategies (3). Many cardiac, pulmonary, and psychiatric complications occur due to long-term bed rest, infection, and critical illness neuropathy/myopathy in COVID-19 patients who cease to use ECMO in the intensive care unit (ICU). Dyspnea, tachycardia, peripheral and respiratory muscle strength losses, loss of functional performance and decreased health-related quality of life are the most common ones (4). Physiotherapy plays an important role in restoring physical function in the subacute phase following ECMO decannulation (5,6). In the rehabilitation of post-COVID patients, respiratory muscle strength training (7,8), lower/upper extremity muscle strength training (resistive), balance and gait training, thoracic mobilization (9) and thoracic muscle stretching (8-10), neuromuscular electrical stimulation (NMES) (8,10) is applied. The intensity, volume, progression and type of exercise should be personalized based on the physical condition and tolerance during the application of the exercise program. We could not find any publication in literature that shared the effects of early post-discharge combined physiotherapy in patients treated with ECMO due to COVID-19. In this study, the effect of the application of the combined physiotherapy program to two patients who received ECMO treatment in the ICU due to COVID-19 and who were discharged, is discussed.

Before and after the treatment, vital signs (heart rate, blood pressure, oxygen saturation and respiratory frequency), dyspnea according to modified Medical Research Council (MRC) were evaluated. Peripheral muscle strength was evaluated with the MRC scale. The scale is rated through a score between 0-60 points. MRC score less than 48 points suggests intensive care-related weakness (11). Respiratory muscle strength was measured using a portable electronic mouth pressure monitor (Micro RPM, Micro Medical Ltd, Kent, UK). Inspiratory muscle strength was measured at residual volume after a maximal expiration (7). The Barthel index was used for functional level. This index is rated

between 0 and 100 points. It is classified as mild, moderate, advanced, fully dependent and independent. As the scores decrease, the level of dependency increases (12). Quality of life was assessed with the Short Form-36 quality of life questionnaire which is involved physical functioning, social functioning, physical role limitations, mental role limitations, mental health, energy/vitality, bodily pain, general health perceptions and it consists of 36 items that measure eight sub-dimensions. Subscales rate health between 0-100, and the higher the score, the better the quality of life (13). The Modified Borg scale was used to rate dyspnea in rehabilitation (9). Informed consent of the patients was obtained for the case reports.

Case Reports

Case 1

A 32-year-old, 35-week pregnant patient was taken to the emergency C/S on the 1st day of diagnosis, after she was tested positive for severe acute respiratory syndrome-coronavirus-2 polymerase chain reaction (PCR) and her Non stress test deteriorated. On the 4th day of her hospitalization, due to deepening of the desaturation of the patient, she was taken to the ICU where pulse methylprednisolone (250 mg/day) and tocilizumab in the dose of 800 mg treatments were administered for 3 days, and she received stem cell therapies 2 times with an interval of 3 days. On the 10th day of her hospitalization, the patient was intubated due to clinical progression and was referred to the 3rd step ICU of the university hospital. The curarized patient was followed in A/C mode and in the prone position for 16 hours a day for 3 days with an application of lung protective mechanical ventilation strategies. When the target oxygenation could not be achieved on the 4th day, she was taken to VV-ECMO support. Empirical broad-spectrum antibiotics, fluid resuscitation, noradrenaline and terlipressin were administered, considering the local flora in the patient who went into septic shock in the follow-up. The patient was extubated on the 10th day of mechanical ventilation and followed up with a high-flow nasal cannula. On the 14th day of the follow-up, the patient was ECMO decannulated. The patient, who was followed up with a reservoir mask, was transferred to the service on the 18th day of the follow-up. She was discharged home after a total of 32 days of hospitalization. After being discharged home, the rehabilitation program was started. No nutritional monitoring was performed at home after discharge. And also

after discharge nutritional recommendations were made according to ESPEN recommendations (14). The detailed results of the pre-rehabilitation evaluations are shown in Table 1 and Table 2.

In the evaluations, the patient was able to stand up with a support of two people, but could not stand without support. At the end of the 10 m assisted walking, the heart rate was 175 beats/min, and shortness of breath occurred with a severity of 9 according to the modified Borg scale. At the end of the evaluation, it was concluded that the patient had inspiratory muscle weakness, cardiac responses, dyspnea, and decreased peripheral muscle strength which prevented exercise. A combined physiotherapy program was applied to the patient for one hour a day for 8 weeks at home. Combined physiotherapy program includes;

1) Respiratory muscle training: Two times a day, 7 days of the week, 15 minutes with Threshold IMT Inspiratory muscle training was performed at 40% of maximum inspiratory pressure (Pimax), combined with pursed lip breathing and thoracic expansion exercises.

2) Resistive muscle strength training: Training was given at 30-80% of a maximum repetition using free weights and dumbbells. Upper extremity was exercised bilaterally

and lower extremity unilaterally. Upper extremity (biceps, triceps, deltoid and rhomboids), lower extremity (hip flexion, hip abduction, knee extension, ankle dorsiflexion) were exercised. Each exercise was coordinated with 10 repetitions and breaths. Rest periods between exercises were kept long.

3) Walking: Five-15 minutes with Borg scale 3-5 intensity, in the following days 0.5 kg weights were attached to each ankles.

4) Balance training: It included standing with eyes open/closed, standing on one leg, trunk rotation.

Exercises were performed with heart rate and oxygen saturation monitoring (10), performed with a scale of 3-5 according to the modified Borg scale. Our patient was a mother who had recently given birth. She could not breast feed due to medications. She wanted to take care of her baby as soon as possible. For that, it was important to develop balance, walking and arm strength in a short time. It was aimed to increase the patient's participation in daily activities, so she was encouraged to take some responsibilities in the kitchen. She was allowed to undertake baby caring activities (changing diapers, sleeping, feeding with a bottle) that she could do while sitting, and she was given the opportunity to develop the relationship with her baby. At the end of

Table 1. The detailed results of the 8 and 4 weeks of pre and post-rehabilitation evaluations of case 1 and 2 respectively

	Case 1 (8 weeks)		Case 2 (4 weeks)	
	Pre-rehabilitation	Post-rehabilitation	Pre-rehabilitation	Post-rehabilitation
Heart rate	156 beats/min	90 beats/min	85 beats/min	78 beats/min
Blood pressure	111/78	115/75	120/80	118/80
SaO ₂	94	99	90	96
Respiratory rate	21 breaths/min	16 breaths/min	28 breaths/min	19 breaths/min
mMRC	3	0	5	1
MRC (0-60)	42	58	53	60
Pimax	62 cmH ₂ O	125 cmH ₂ O	68 cmH ₂ O	132 cmH ₂ O
Pimax %	71.80	144.75	64	124.23
Barthel index	50	100	35	90
SF-36 physical functioning	0	80	0	80
SF-36 physical role limitations	0	50	0	25
SF-36 emotional role limitations	0	66.66	0	100
SF-36 energy/vitality	25	75	10	85
SF-36 mental health	48	72	16	72
SF-36 social functioning	0	100	0	75
SF-36 bodily pain	0	80	0	90
SF-36 general health perceptions	0	55	20	65

mMRC: Modified Medical Research Council, MRC: Medical Research Council, Pimax: maximal inspiratory pressure, SaO₂: oxygen saturation, SF-36: Short Form-36

Table 2. The results of the pre and post-rehabilitation MRC scores

	Case 1		Case 2	
	1 st week right/left	8 th week right/left	1 st week right/left	4 th week right/left
Shoulder abduction	3/3	5/4	5/4	5/5
Elbow flexion	4/4	5/5	5/5	5/5
Wrist extension	4/3	5/5	5/4	5/5
Hip flexion	4/3	5/4	4/4	5/5
Knee extension	4/4	5/5	5/4	5/5
Ankle dorsiflexion	3/3	5/5	4/4	5/5
MRC: Medical Research Council				

the combined rehabilitation program, the rate of exertional dyspnea decreased. Resting heart rate decreased, reaching the limits of normal heart rate (85 beats/min). The patient's respiratory muscle strength and peripheral muscle strength increased. By the end, her functional level improved and her quality of life increased. The bilateral diffuse pulmonary infiltration of the patient during her hospitalization in the ICU and her images with marked regression after combined physiotherapy program are shown in Figure 1A and 1B respectively. The detailed results of the post-rehabilitation evaluation are shown in Table 1 and Table 2.

Case 2

A 63-year-old male patient applied to a health institution due to increased dyspnea while receiving oral methylprednisolone and long-term oxygen therapy at home due to a previous COVID-19 infection. The blood test's results were as; white blood cell: $22.51 \times 10^3/\mu\text{L}$, ferritin: 98.1 $\mu\text{g/L}$, C-reactive protein: 324.9 mg/L and procalcitonin: 0.52 $\mu\text{g/L}$ and the patient needed High Flow. Thorax tomography showed interlobular septal thickenings, traction bronchiectasis, diffuse ground glass opacities and crazy paving appearance. Trimethoprim and sulfamethoxazole treatment was started empirically for potential *Pneumocystis carinii* pneumonia. He was intubated on the fourth day with progressive desaturation, and was taken to VV-ECMO due to her hypoxemic course. Subsequently, bronchoalveolar lavage was performed and PCP-PCR was positive. On the fourth day of ECMO application, oxygen demand and bilateral infiltrations on chest X-ray decreased, and she was followed

by awake ECMO protocol. On the 7th day of ECMO, when the partial oxygen pressure did not decrease and hypercapnia did not develop in the 24-hour follow-up, he was decannulated with the support of sweep gas flow: 1 L/min and FiO_2 : 21%. He was discharged with a nasal cannula on the 10th day of follow-up and a combined rehabilitation program was started at home on the second day. No nutritional monitoring was performed at home after discharge. And also after discharge nutritional recommendations were made according to

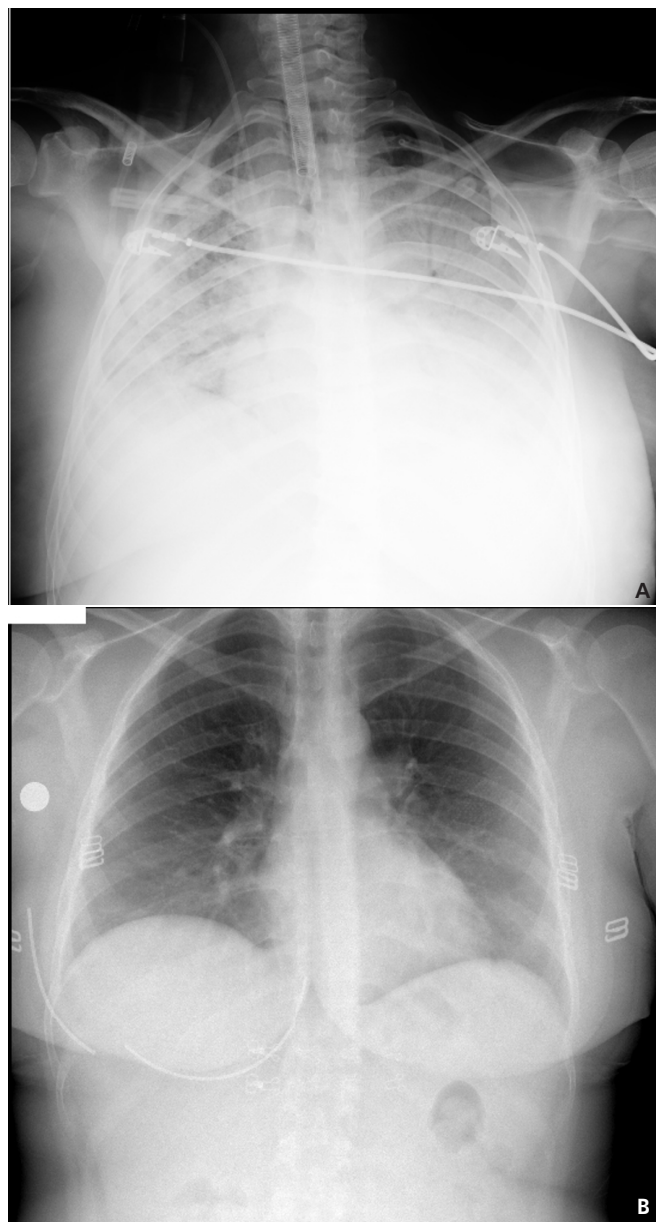


Figure 1. A. Image of case 1 during her hospitalization in the intensive care unit. B. Image of case 1 after combined physiotherapy program

ESPEN recommendations (14). The detailed results of the pre-rehabilitation evaluation are shown in Table 1 and Table 2.

In the pre-rehabilitation evaluation, the patient did not have cough and sputum complaints. The patient was able to stand up with a support of two people, but could not stand alone. Resting dyspnea was 5 on the Modified Borg scale. Decreased peripheral muscle strength and shortness of breath prevented exertion. After considering the results of the evaluation, a combined rehabilitation program was planned for the patient. In addition, NMES for rapid recovery of muscle strength and autogenic relaxation training for dyspnea control were added to the program. This program was applied to the patient for one hour a day for 4 weeks at home. Combined physiotherapy program;

1) Respiratory muscle training: Two times a day, 7 days of the week, 15 minutes with Threshold IMT Inspiratory muscle training was performed at 40% of Pimax, combined with pursed lip breathing and thoracic expansion exercises. Thoracic mobilization: This included stretching and autogenic relaxation of the m. latissimus dorsi, m. pectoralis major/minor, m. serratus anterior and m. trapezius muscles.

2) Resistive muscle strength training: Training was given at 30-80% of a maximum repetition using free weights and dumb-bells. The upper extremity was operated bilaterally and the lower extremity unilaterally. Upper extremity (m. biceps, m. triceps, m. deltoid and m. rhomboids), lower extremity (hip flexion, hip abduction, knee extension, ankle dorsi flexion) were exercised. Each exercise was coordinated with 10 repetitions and breaths. Rest periods between exercises were kept long.

3) Walking: In the second week, out-of-bed movements were started, 5-15 minutes, Borg scale 3-5 intensity, in the following days 0.5 kg weights were attached to each ankles. The last 3 sessions of stair climbing exercise were performed.

4) Balance training: It included standing with eyes open/closed, standing on one leg, trunk rotation.

5) NMES: NMES was applied to the m. tibialis anterior, and m. quadriceps femoris muscles at 50 Hz, 350-400 ms for 20 minutes.

Exercises were performed with heart rate and oxygen saturation monitoring (10). They were performed according to the modified Borg scale with a severity of 3-5. The patient was the coach of a football team and he wanted to go training as soon as possible. Dependence on oxygen concentrator and low effort-related functional performance decreased his

exercise motivation. We performed some exercises using soccer balls like holding balls that thrown at different angles or raising the ball in the air. At the end of the combined treatment, peripheral muscle strength increased, respiratory muscle strength developed, and accordingly, dyspnea that developed with exertion decreased. The patient was able to climb stairs and walk unassisted without the need for nasal oxygen intake. Correlative to this, the patient's functional level improved and his quality of life increased. The bilateral diffuse pulmonary infiltration of the patient during his hospitalization in the ICU and his images with marked regression after combined physiotherapy program are shown in Figure 2A and 2B respectively. The detailed results of the post-rehabilitation evaluation are shown in Table 1 and Table 2. At the end of the 4th week, the patient was able to oversee the training of the football team.

Discussion

Long-term mechanical ventilation, ECMO therapy and high-dose corticosteroids affect patients' recovery after discharge. Patients' pulmonary function may be significantly reduced due to alveolar damage in the early post-weaning phase (5). Peripheral and respiratory muscle atrophies due to prolonged bed rest reduce the quality of life in patients (15,16). Nutritional support, especially protein intake, is very important for muscle strength during acute illness. Nutritional goals were determined for each patient during their intensive care hospitalization, taking into account the ESPEN guideline recommendations (14). According to early enteral nutrition and disease phases (acute phase-early period, acute phase late period or late phase), nutritional and protein targets have been tried to be achieved (14). There was no statistically significant effect of interventional nutrition on muscle mass or muscle strength and walking speed. However, according to AWGS 2019, the combination of nutrition and exercise therapy can improve muscle strength and function (17). In the early period after extubation, patients have muscle weakness and loss of motor function, and the combination of exercise and nutrition in this period gives better results in order to achieve recovery (18).

Therefore, it is important to start physiotherapy early in the hospital and after discharge (5,19,20). There is little evidence of early rehabilitation after ECMO decannulation for COVID-19 patients. In a case series, a rehabilitation, including extremity movements, sitting, in-bed cycling, respiratory

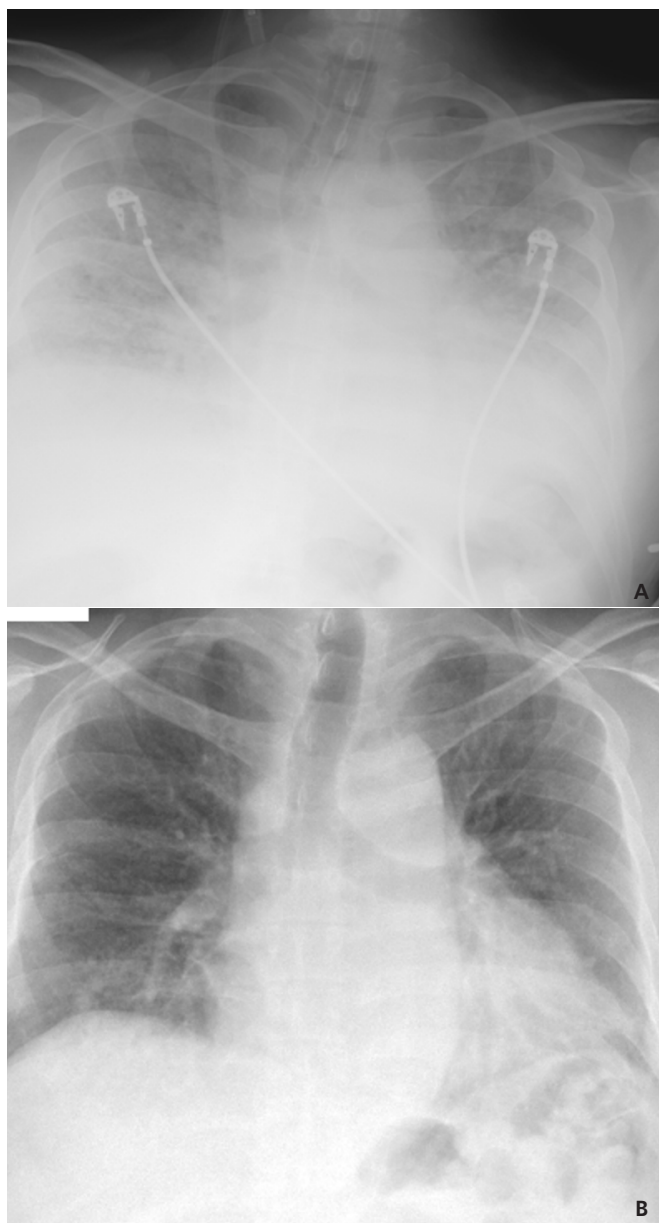


Figure 2. A. Image of case 2 during his hospitalization in the intensive care unit. B. Image of case 2 after combined physiotherapy program

muscle training and muscle strength training, was applied after ECMO decannulation in patients who underwent lung transplantation due to COVID-19-related pulmonary fibrosis (6). It has been stated that rehabilitation plays a very important role in the subacute phase by restoring physical function after ECMO decannulation (5,6). The effects of multi-component therapeutic exercises on dyspnea, functional performance

and quality of life in COVID-19 patients after weaning and discharge from ICU have been shown (9). Strengthening, balance and respiratory muscle training should be included in patient follow-up programs. Physiotherapists should individualize their treatment programs and aim to monitor side effects and symptoms (21). Rehabilitation programs should be prepared with a holistic perspective to manage post-COVID-19 symptoms. At the same time, rehabilitation should be planned according to the patients' comorbidities, current functional and cognitive status (21). Although the needs of the patients we mentioned in our study were similar, their responses to exercise during treatment were different. Case 1 completed the exercises with a higher heart rate response, while the second case finished the exercises with a higher dyspnea score and low oxygen saturation. For this reason, the recovery time after each set was determined by taking these personalized answers into consideration. Early combined physiotherapy application improved the functional capacities, respiratory muscle strength and peripheral muscle strength of the patients in a short time, thus improving the walking capacity and accordingly the life quality.

Our study shows the positive effects of early combined physiotherapy after decannulation in patients receiving high-level invasive support such as mechanical ventilation and ECMO due to COVID-19 infection. After ECMO decannulation in COVID-19 patients, the early combined rehabilitation program enabled patients to recover in a short time and to participate in daily activities.

Ethics

Informed Consent: Informed consent of the patients was obtained for the case reports.

Peer-review: Externally peer-reviewed.

Authorship Contributions

Surgical and Medical Practices: N.E., A.O.K., M.Ö.A., M.P.K., Concept: N.E., M.P.K., Design: N.E., M.P.K., Data Collection and/or Processing: N.E., A.O.K., M.P.K., Analysis and/or Interpretation: N.E., A.O.K., M.P.K., Literature Search: N.E., Writing: N.E., M.Ö.A., M.P.K.

Conflict of Interest: No conflict of interest was declared by the authors.

Financial Disclosure: The authors declared that this study received no financial support.

References

1. Australia and New Zealand Extracorporeal Membrane Oxygenation (ANZ ECMO) Influenza Investigators, Davies A, Jones D, Bailey M, Beca J, Bellomo R, Blackwell N, et al. Extracorporeal Membrane Oxygenation for 2009 Influenza A(H1N1) Acute Respiratory Distress Syndrome. *JAMA* 2009;302:1888-95.
2. Noah MA, Peek GJ, Finney SJ, Griffiths MJ, Harrison DA, Grieve R, et al. Referral to an extracorporeal membrane oxygenation center and mortality among patients with severe 2009 influenza A(H1N1). *JAMA* 2011;306:1659-68.
3. Shekar K, Badulak J, Peek G, Boeken U, Dalton HJ, Arora L, et al. Extracorporeal Life Support Organization Coronavirus Disease 2019 Interim Guidelines: A Consensus Document from an International Group of Interdisciplinary Extracorporeal Membrane Oxygenation Providers. *ASAIO J* 2020;66:707-21.
4. Sheehy LM. Considerations for Postacute Rehabilitation for Survivors of COVID-19. *JMIR Public Health Surveill* 2020;6:e19462.
5. Zhu C, Wu Y, Liu H, Ban Y, Ma X, Zhang Z. Early pulmonary rehabilitation for SARS-CoV-2 pneumonia: Experience from an intensive care unit outside of the Hubei province in China. *Heart Lung* 2020;49:449-50.
6. Mao L, Luo L, Wang D, Yu Y, Dong S, Zhang P, et al. Early rehabilitation after lung transplantation with extracorporeal membrane oxygenation (ECMO) of COVID-19 patient: a case report. *Ann Transl Med* 2021;9:512.
7. El Naggar TE, Obaya HE, Ismail AF, Azzam RE, El Naggar AE. Inspiratory Muscle Training Prevents Diaphragmatic Atrophy in Mechanically Ventilated COVID-19 Patients. *IJMA* 2021;3:1761-71.
8. Siddiq MAB, Rathore FA, Clegg D, Rasker JJ. Pulmonary Rehabilitation in COVID-19 patients: A scoping review of current practice and its application during the pandemic. *Turk J Phys Med Rehabil* 2020;66:480-94.
9. Udina C, Ars J, Morandi A, Vilaró J, Cáceres C, Inzitari M. Rehabilitation in adult post-COVID-19 patients in post-acute care with Therapeutic Exercise. *J Frailty Aging* 2021;10:297-300.
10. Gautam AP, Arena R, Dixit S, Borghi-Silva A. Pulmonary rehabilitation in COVID-19 pandemic era: The need for a revised approach. *Respirology* 2020;25:1320-2.
11. Bestall JC, Paul EA, Garrod R, Garnham R, Jones PW, Wedzicha JA. Usefulness of the Medical Research Council (MRC) dyspnoea scale as a measure of disability in patients with chronic obstructive pulmonary disease. *Thorax* 1999;54:581-6.
12. Simonelli C, Paneroni M, Vitacca M, Ambrosino N. Measures of physical performance in COVID-19 patients: a mapping review. *Pulmonology* 2021;27:518-28.
13. Koçyiğit H, Aydemir Ö, Ölmez N, Memiş A. Kısa Form-36 (KF-36)'nın Türkçe versiyonunun güvenilirliği ve geçerliliği. *İlaç ve Tedavi dergisi* 1999;12:102-6.
14. Singer P, Blaser AR, Berger MM, Alhazzani W, Calder PC, Casaer MP, et al. ESPEN guideline on clinical nutrition in the intensive care unit. *Clin Nutr* 2019;38:48-79.
15. Abodonya AM, Abdelbasset WK, Awad EA, Elalfy IE, Salem HA, Elsayed SH. Inspiratory muscle training for recovered COVID-19 patients after weaning from mechanical ventilation: A pilot control clinical study. *Medicine (Baltimore)* 2021;100:e25339.
16. Koukourikos K, Tsaloglidou A, Kourkouta L. Muscle atrophy in intensive care unit patients. *Acta Inform Med* 2014;22:406-10.
17. Chen LK, Woo J, Assantachai P, Auyeung TW, Chou MY, Iijima K, et al. Asian Working Group for Sarcopenia: 2019 Consensus Update on Sarcopenia Diagnosis and Treatment. *J Am Med Dir Assoc* 2020;21:300-7.e2.
18. Takehi S, Wakabayashi H, Inuma H, Inose T, Shioya M, Aoyama Y, et al. Rehabilitation Nutrition and Exercise Therapy for Sarcopenia. *World J Mens Health* 2022;40:1-10.
19. Polastri M, Swol J, Loforte A, Dell'Amore A. Extracorporeal membrane oxygenation and rehabilitation in patients with COVID-19: A scoping review. *Artif Organs* 2022;46:30-9.
20. Morris K, Osman L. Physiotherapy on ECMO: Mobility and beyond, Qatar Medical Journal, 4th Annual ELSO-SWAC Conference Proceedings 2017:58.
21. Daynes E, Gerlis C, Chaplin E, Gardiner N, Singh SJ. Early experiences of rehabilitation for individuals post-COVID to improve fatigue, breathlessness exercise capacity and cognition - A cohort study. *Chron Respir Dis* 2021;18:14799731211015691.